AUGMENTED FLAP RECONSTRUCTION OF COMPLEX PRESSURE ULCERS UTILIZING NANOFIBER SURGICAL MATRIX

Mary Vallery, RN, WCC, OMS[1]; Thomas Shannon, MD, CWSP[1]

[1]*Nexus Specialty Hospital, Shenandoah, Texas 77384*

NEXUS SPECIALTY HOSPITAL
A Nexus Health Systems Facility

PRIMARY AIM:

Evaluate the role and efficacy of a novel nanofiber surgical matrix in flap reconstruction of chronic pressure ulcers in long term acute care patients with multiple comorbidities.

INTRODUCTION: Flap reconstruction of pressure ulcers offers an important clinical means of decreasing morbidity in hospitalized patients. Unfortunately, complication rates following pressure ulcer reconstruction utilizing flap coverage are reportedly high as patients commonly possess multiple risk factors for postoperative dehiscence, infection, and ulcer recurrence. The primary aim of this case series was to examine whether preparation of pressure ulcers with a novel nanofiber surgical matrix may reduce the rate of wound healing complications, readmissions, and re-operations following flap reconstruction.

METHOD: Cases involving pressure ulcer coverage at a long-term acute care facility were reviewed and clinical outcomes were summarized. Data were retrospectively collected via chart review by the treating physician at Nexus Specialty Hospital in Shenandoah, TX. Data from wound care patients treated with nanofiber surgical matrix between May 2019 and October 2019 were included in the study. In all cases wounds were prepared and debrided prior to one application of nanofiber surgical matrix *(Restrata® Wound Matrix, Acera Surgical, Inc., St. Louis, MO)*. The nanofiber surgical matrix was fenestrated and sutured in place with an overlying non-adherent dressing and left in the wound bed to encourage granulation tissue formation prior to flap reconstruction.

RESULTS: Cases 1-3 involved males between 19-53 year olds who presented with chronic pressure wounds >4-12 months to the left ischial spine, left trochanter, and right ischial spine respectively, secondary to tetra/paraplegia. Ulcers were initially debrided and treated with nanofiber surgical matrix in order to encourage granulation tissue formation and improve tissue quality. Rotational flap reconstruction with muscle and skin was performed 4-7 days later and all wounds remained intact >4 weeks post operatively with healthy margins and no signs of dehiscence or infection. Case 4 involved a 47-year-old female with Hurler syndrome who presented with a chronic stage 4 pressure ulcer to the left trochanteric prominence. Debridement was performed and the wound treated with nanofiber surgical matrix and reconstructed with rotational flap 5 days later. The wound remained intact with no signs of dehiscence or infection 6 weeks post operatively. Case 5 involved a 61-year-old male who presented with an abdominal wound complicated by a myelodysplastic syndrome. The wound was initially debrided and treated with nanofiber surgical matrix followed by closure 12 days later. Wound remained closed up to four weeks post operatively. Case 6 involved a 50-year-old female on hemodialysis who presented with a 3-monthold ischemic ulcer on the posterior aspect of the lower left leg measuring 12 cm x 6 cm. The ulcer was initially debrided and treated with nanofiber surgical matrix to test tissue adherence. Four weeks later rotational flap reconstruction was performed. 12 weeks post operatively, the wound is with minor dehiscence albeit with healthy margins and no signs of infection measuring 2 cm x 2 cm.

CONCLUSIONS: Together, these results suggest that pre-conditioning of complex pressure ulcers with nanofiber surgical matrix may improve tissue quality and maximize the efficiency and success of flap coverage. Futures studies will aim to build upon these findings and expand the investigation of augmented flap reconstruction to a larger subset of patients across multiple health care facilities

BACKGROUND:

Nanofiber surgical matrix is similar to human ECM and supports cell ingrowth, retention, and granulation tissue formation[1]

NANOFIBER SURGICAL MATRIX

Resorbable Electrospun Matrix

» Restrata® Wound Matrix *(Acera Surgical, Inc., St. Louis, MO)* is the only flexible, suturable, electrospun, nanofiber matrix for use in encouraging wound healing.

» The matrix is composed of non-woven, resorbable synthetic nanofibers whose structure and architecture mimics that of native ECM.

» Due to its unique design, the matrix resists enzymatic degradation, persists in the wound bed, has excellent biocompatibility, and supports cellular/tissue ingrowth.

» The unique properties of the nano fiber matrix also offers ease-of-use and clinical versatility with significant logistical advantages over existing amniotic / allogenic / biologic products.

» The nanofiber matrix exhibits structural attributes similar to native extracellular matrix.

» Electrospun nanofibers support cellular ingrowth, retention, and differentiation while directing and enhancing cellular activity.

» The porosity and progressive resorbtion of the matrix supports continued cellular infiltration, tissue formation, and neo-vascularization.

» Prior studies confirm nanofiber materials are a unique alternative to allografts / xenografts[2].

Nanofiber Matrix



Human ECM



Processed Xenograft

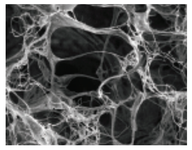

Nanofiber material promotes rapid cellular infiltration and activation

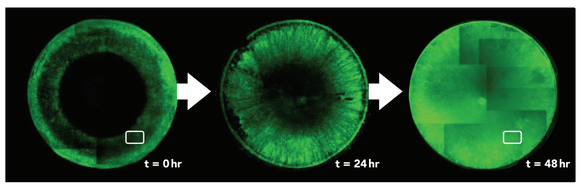

METHODS:

Nanofiber surgical matrix applied to encourage granulation prior to flap reconstruction

» Data were retrospectively collected via chart review by the treating physician at Nexus Specialty Hospital in Shenandoah, TX. Data from wound care patients treated with nanofiber surgical matrix between May 2019 and October 2019 were included in the study. Patient eligibility for treatment with the nanofiber wound matrix was based on wound type, wound severity, and wound duration *(4 weeks or greater)*.

» The nanofiber surgical matrix was applied once prior to flap reconstruction and based on physician assessment of wound status. Before treatment, sharp debridement of the wound margins and wound bed was performed.

» The nanofiber surgical matrix was directly applied to the wound bed and secured in place with staples or sutures. An overlying non-adherent dressing was applied to prevent secondary dressings from adhering to the nanofiber matrix. An appropriate secondary dressing was then applied. The nanofiber matrix was left in the wound bed until the time of flap reconstruction and was not disturbed or removed.

All wounds underwent appropriate debridement

Nanofiber wound matrix was thoroughly fenestrated

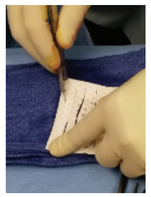

Matrix was applied with non-adherent dressing

RESULTS:

Wounds treated with nanofiber matrix demonstrated rapid granulation tissue formation which encouraged successful and lasting wound closure upon flap reconstruction

CASE #1: Left Ischial Ulcer

» 53yo M, C5 quadriplegia since 1986
» Wound open for >12 mos
» Failed NPWT therapy
» Applied Restrata®, Flapped 7 days later
» Lasting closure 12 wks post-op

CASE #2: Trochanteric Pressure Ulcer

» 19yo M, Neuromyelitis, functional quadriplegia
» Wound open for >4 mos
» Failed NPWT therapy
» Applied Restrata®, Flapped 4 days later
» Lasting closure 9 wks post-op

CASE #3: Ischial Pressure Ulcer

» 44yo M, C5-6 incomplete quadriplegia
» Wound open for >6 mos
» Failed topical wound therapy
» Applied Restrata®, Flapped 7 days later

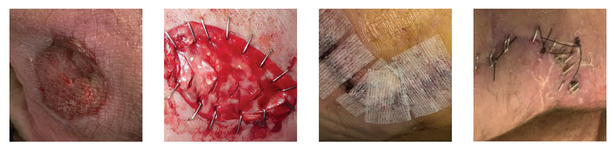

CASE #4: Trochanteric Pressure Ulcer

» 47yo F, Hurler syndrome with MR
» Wound open for >6 mos
» Failed NPWT therapy
» Applied Restrata®, Flapped 5 days later
» Lasting closure 6 wks post-op

CASE #5: Abdominal Wound

» 61yo M, Clotting factor disorder
» Abscess debrided and open for 2 wks
» Applied Restrata®, Flapped 12 days later

CASE #6: Lower Extremity Wound

» 50yo F, Calciphylaxis on hemodialysis
» Wound open for >3 mos
» Failed topical wound therapy
» Applied Restrata®, Flapped 14 days later
» Significant PAR, 12 wks post-op @ 2x2cm

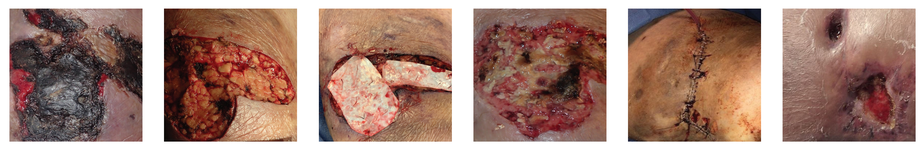

CONCLUSIONS: Nanofiber matrix provides significant benefits in maximizing flap reconstructions